



PATIENT

Boo Leja

SPECIES

Canine

BREED

Mix

SEX

Male Neutered

AGE

10 years

WEIGHT

24.7lbs

PRESENTING CLINICAL SIGNS

History: Boo was noted to have a transient gallop in November. He is scheduled for some dental work. He is presently doing well with a good appetite and activity level. He has no current C/S/V/D/PU/PD. On exam, NSR, grade IV/VI murmur with PMI left apical area radiating to right, PSS, lung fields clear. BP: 150mmHg x 5. *Sedated with propofol for study.

ECHOCARDIOGRAM FINDINGS

2D, m-mode, color flow and Doppler imaging is available.

Left ventricle: The LV diameter is normal with adequate myocardial function. LV wall thicknesses are normal.

Left atrium: The left atrium is normal.

Mitral valve: The mitral valve is mildly thickened with no prolapse into the left atrial lumen. Mild eccentric mitral regurgitation with a normal velocity.

Aortic valve/aorta: The aortic valve is normal in morphology and mobility. Normal aortic outflow velocity; laminar flow. No aortic insufficiency.

Right ventricle: Normal right ventricular diameter and morphology indicating no overt evidence of pulmonary arterial hypertension.

Right atrium: Normal RA dimension.

Tricuspid valve: The tricuspid valve appears normal with trace tricuspid regurgitation; normal velocity.

Pulmonic valve/pulmonary artery: The pulmonic valve is normal in morphology and mobility. No pulmonic insufficiency. Normal RVOT velocity; laminar flow.

Pericardium/other: No pericardial or pleural effusion noted. No obvious cardiac masses.

Heart rhythm: ECG reveals a sinus rhythm with an average HR of 188bpm.

INTERPRETED BY

Maggie Machen
Lamy, DVM
DACVIM (Cardiology)

2-Dimensional Measurements

Ao diam (cm)	2.0
LA diam (cm)	2.1
LA:Ao (Swe)	1.1
IVS thickness (cm)	0.67
LVID diastole (cm)	2.5
PW thickness (cm)	0.63
LVID systole (cm)	1.2
FS (%)	52

Doppler Measurements

PV Vmax (m/s)	0.7
AoV Vmax (m/s)	0.98
MR Vmax (m/s)	5.6
TR Vmax (m/s)	1.9
TR PG (mmHg)	15

IMAGING

PERFORMED BY

Pamela Harrigan,
RDCS

INTERPRETATION OF THE FINDINGS

The cause of the murmur is chronic degenerative valve disease causing mild mitral and trace tricuspid regurgitation. Lack of significant left atrial enlargement indicates the current risk for complication is low. No concurrent issues such as pulmonary hypertension are noted in this study.

HOSPITAL NAME

Mass Veterinary Services

REFERRING VET

Dr. Masloski

Assessment of progression in the future will help predict long term prognosis, which is highly variable at this stage (B1).

INVOICE

23099

RECOMMENDATIONS

- In an asymptomatic dog without significant left atrial enlargement, no cardiac medications are clearly indicated.
- Omega fatty acid supplementation and mild salt restriction may be of some long-term benefit.

DATE

3/15/22



PATIENT

Boo Leja

- No cardiac contraindication for general anesthesia prior to chamber enlargement.
- Monitor for development of a cough, labored breathing, exercise intolerance or collapse episodes.

SPECIES

Canine

PLAN

- Recommend conservative monitoring with a recheck echocardiogram in 6-12 months, sooner if any development of clinical signs.

BREED

Mix

SEX

Male Neutered

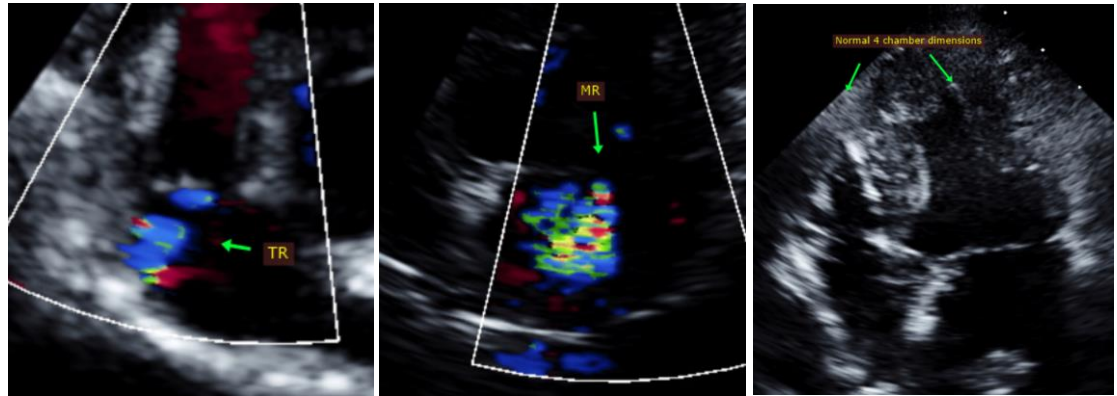
AGE

10 years

WEIGHT

24.7lbs

IMAGES



The information and recommendations provided are based on the images presented by the referring veterinarian. No evaluation can be communicated regarding pathology that was not visible in the image/video clips provided.

INTERPRETED BY

Maggie Machen
Lamy, DVM
DACVIM (Cardiology)

Thank you for this referral. This report was generated using transcription software, and minor dictation errors may be present. If the clinical or image interpretation does not parallel your findings or if I can be of any further assistance, please contact me.

IMAGING PERFORMED BY

Pamela Harrigan,
RDCS

Maggie Machen Lamy, DVM
Diplomate of the American College of Veterinary Internal Medicine (Cardiology)
info@sonopath.com

Echocardiogram performed by:

Pamela Harrigan, RDCS
Pet Animal Ultrasound Service (4paus.com)

HOSPITAL NAME

Mass Veterinary Services

REFERRING VET

Dr. Masloski

INVOICE

23099

DATE

3/15/22